

What's

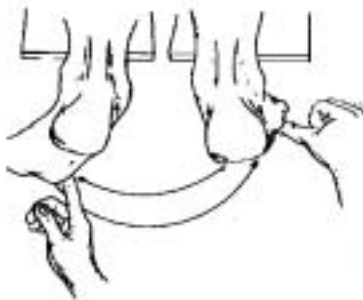


Afoot

Mechanics of Subtalar joint motion and its effect on Posture

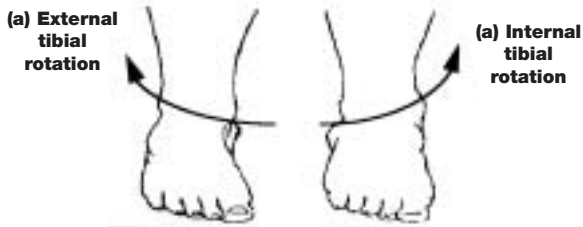by Phillip Vasyli, Podiatrist

The Subtalar joint primarily exhibits the tri-planar motions of Pronation and Supination. During weight bearing, pronation



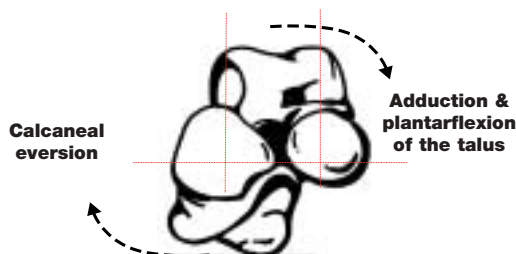Diag 1. Posterior view of right foot. (Open chain or non weight bearing motion)

is commonly associated with internal tibial rotation and lowering of the arch structures, whilst supination is commonly associated with external tibial rotation and raising of the arch structures.

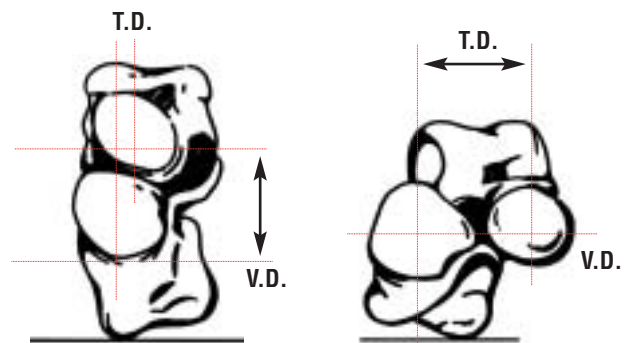


Diag 2. Anterior view of right foot showing external & internal tibial rotation associated with closed chain kinetic subtalar joint supination & pronation.

An excessively pronated foot is represented by eversion of the calcaneus, adduction and plantarflexion of the talus whilst the supinated foot is represented by calcaneal inversion, talus abduction and dorsiflexion. Therefore, a patient suffering from unilateral excess pronation may experience excess medial loading and functional shortening of the effected leg.



Diag 3. Anterior view of right Subtalar joint



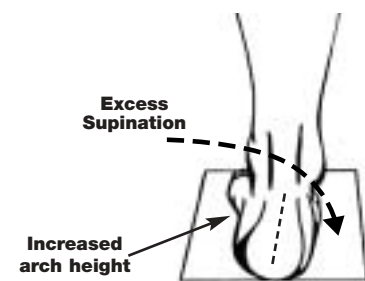
(Anterior view of right subtalar joint showing motion of the talus on the calcaneus.)

Diag 4. Pronation effectively increases the transverse distance (t.d.) associated with internal tibial rotation whilst simultaneously decreasing the vertical distance (v.d.).

Therefore, excessively pronated feet are commonly represented by lowered arch structures, flexed knee and hip positions due to excessive internal lower limb rotation. The muscular and associated soft tissue structures are subsequently compromised and common problems ranging from patello-femoral dysfunction to low lumbar stress syndrome are commonly related to this type of posture.

Conversely, excessively supinated feet commonly represent as pes cavus (high arch) foot types with reduced shock absorption qualities and lateral instability problems.

Excess supination with closed chain kinetic motion externally rotates the tibia, increasing the vertical distance (v.d.) and inverting the calcaneus. The combination of raising the arch structure, locking the midfoot and inverting the calcaneus subsequently reduces the shock absorbing qualities of the foot and leg, while increasing lateral instability of the lower limb structures.



This foot type is commonly attributed to chronic inversion sprain syndrome, ilio-tibial band syndrome & shock reduction symptoms. #

